



Report ID : 125756

ABDOMEN CT SCAN REPORT

Name of the Patient :	نوال محمد علي الجدري	Age :	42 سنة	Sex :	انثى
Referred from :	Prof.Yahya Ghanem	Date :	31/07/2024		

(PLAIN WITH ORAL AND IV CONTRAST)

Spiral CT of the abdomen was performed and revealed:

- Normal sized liver with no focal lesion. Biliary system and portal tract are normal.
- Normal sized GB with no stones or abnormal wall thickening.
- Pancreas, spleen, both kidneys and adrenals are normal.
- No sizable nodal enlargement or measurable amount of fluid collection in the abdomino-pelvic cavities.
- Normal UB wall thickness with no stones or intravesical growth.
- Normal sized uterus with AVF position and mild deviation to left (variation). No focal lesion in its tissue. Normal endometrial thickness. Normal size and structure of both ovaries.
- No significant bone abnormalities.
- No localized lesion in the scanned basal pulmonary fields.

OPINION:-

- Moderately distended gaseous bowels with no sizable mass lesion or abnormal wall thickening along the course of alimentary tract. No sizable pathological nodal enlargement or measurable amount of fluid collection in the abdomino-pelvic cavities.
- Normal sized liver with no focal lesion in its tissue.
- GB, pancreas, spleen, both kidneys and adrenals are normal.

Dr. Osama Dawood MD
 Radiologist



Center of dr.Yahya Ghanem
consultant of gastoro. Hepato.
& endoscopy unite.



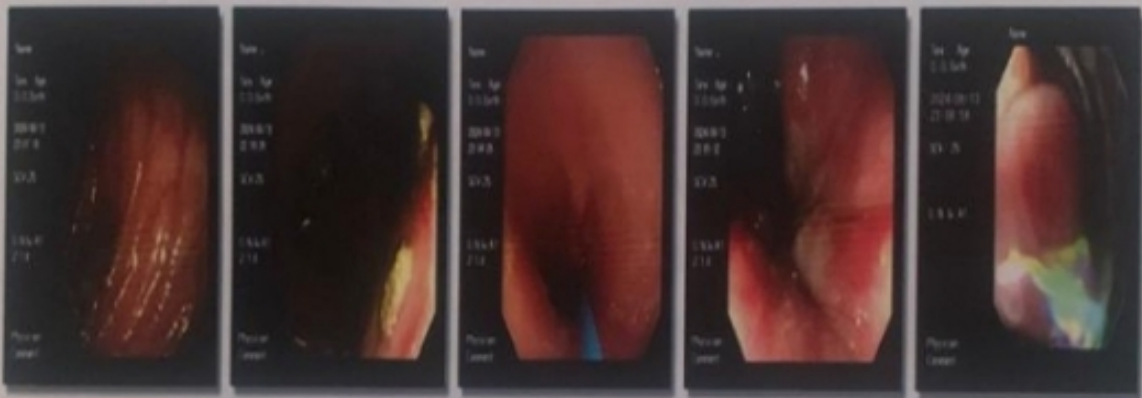
مركز الدكتور يحيى غانم
التخصصي

COLONOSCOPY

Name: NWAAL MOHAMED ALI ALJEDREI : SEX: FEMALE AGE: 42 Date: 31-7.2024

Type: TOTAL COLONOSCOPY H B AND HIV -VE AND C V - VE C.O. ANEAMIA FOR INVESTIGATION

Referred By :DR: YAHYA GHANEM /



ANAL VERGE : NAD .

RECTUM : INTERNAL HEAMORRHOIDE GRADE 2-23 BANDED .

RECTOSEGMOIDE MUCOSA : PROCTOSEGMOIDITIS

COLONIC MUCOSA ; NAD

CONCLUSION : INTERNAL HEAM., GRADE 2-3 AND PROCTOSEGMOIDITIS .

BIOPSY : TAKEN

DR : YAHYA A. GHANEM

ENDOSCOPIST



20240824150646



مختبرات أيلاب الطبية التخصصية
ILAB SPECIALIZED MEDICAL LABORATORIES

د. وائل العيسى
لشخصيات علم الأورام
بالتشخيص النسيجي والجراح

د. يسر عبدالهادي
مختبري فحوصات الجينات

د. فوزي العمراني
التخصصي في أمراض الكلى

د. ملال القحطاني
استشاري فحوصات الكلى
والعلاج

PATIENT DATA

Name: نوال محمد علي الجري
Age: 42
Sex: F

SPECIMEN DATA

Collected: 2024-08-13
Received: 2024-08-13
Reported: 2024-08-24
Code #: S12833-24

PHYSICIAN DATA

د. يحيى علي غانم

PATHOLOGY REPORT

CLINICAL INFORMATION Anemia and abdominal pain, colonoscopy: Proctosigmoiditis.

NATURE OF SPECIMEN Colonoscopic biopsy

GROSS

Specimen received consists of multiple whitish tissue pieces measuring 0.7x0.4x0.3 cm in aggregate; totally submitted.

MICROSCOPIC

Serial sections examined from the specimen received revealed pieces of colonic mucosa showing slightly distorted tubular glands lined by columnar mucus-secreting cells entangling many Goblet cells. The underlying crypts are lined by cubical cells showing evidence of mild regenerative activity. The lamina propria is mildly edematous showing infiltration by mild numbers of lymphocytes together with few lymphoid aggregates. No evidence of granulomatous inflammation or specific parasitic infestation. No evidence of atypical changes or malignancy in received biopsy.

FINAL DIAGNOSIS

Colon, Colonoscopic biopsy, MILD CHRONIC NON SPECIFIC COLITIS. No Malignancy.

Thanks for reference

Dr. WAEL AL-ABSI
Pathology Specialist

Wael Absi

1/1

Email: info@ilab-ye.com Website: www.ilab-ye.com

خدمة العملاء

77 64 0 64 64
7 38 35 77 90

+967 773 844 539

+967 773 807 804

+967 733 045 971

Abdulaziz Alkhatib - Head of Lab

Abdulaziz Alkhatib - Head of Lab

Abdulaziz Alkhatib - Head of Lab

فرع لاشارع

أبراج صماء الطبية - شارع نهر
جوار الشارقة مول - صماء
01 60 36 63 - 77 006 36 63

الفرع الرئيسي

برج اليمن الطبي - شارع الستين
جوار مستشفى أزال الجديد - صماء
01 38 77 90 - 777 807 804



تحرير



عرض المحمول



مركز الأمسين الطبي

الكشفة التلفزيونية

الاسم
مرسل من

عناصر مساعد

ULTRASOUND

عجلة
الأحد ١٩ أيار ٢٠٢٤ م

العصر
التاريخ

ABDOMINAL U/S REPORT

<u>Liver</u>	Normal size and texture No focal lesion Normal PV. & CBD
<u>Gall Bladder</u>	normal size and wall thickness . No stone
<u>Pancreas</u>	Normal size and texture
<u>Spleen</u>	normal size and texture .no focal lesion
<u>Rt. Kidney</u>	Normal size =99x34 mm .Normal texture.Normal CMD Multiple calyceal microstones .No backpressure.normal parenchymal thickness=16--18 mm
<u>Lt. Kidney</u>	Normal size =106x52 mm .Normal texture.Normal CMD No stone or backpressure.normal parenchymal thickness=7--19 mm
<u>Urinary Bladder</u>	Normal size and wall thickness No stone or tumor
<u>Uterus</u>	Normal size=8.3x4.4 cm,with normal texture and normal AV.position Normal thickening and shape of endometrium . No gestational sac
<u>Ovaries</u>	Both are normal sizes (RO=2.9x2 cm and LO=3x2.1 cm).Normal texture. no cyst
<u>Puch of Doglaus</u>	Free

CONCLUSION

MILDLY THICKENED WALL ASCENDING COLON (COLITIS).

RT_KIDNEY : Normal size =99x34 mm .Normal texture.Normal CMD

Multiple calyceal microstones .No backpressure.normal parenchymal thickness=16--18 mm

LT_KIDNEY : Normal size =106x52 mm .Normal texture.Normal CMD

No stone or backpressure.normal parenchymal thickness=17--19 mm .

ODERATE GASEOUS LARGE BOWELS .

Dr. Tawfik B

MED, LAB.

A.AL-Homydy

d-Lab



معية للتحاليل الطبية

الحفيظ الحميدي

مختبرات طبية

العمر : 42 year F : الجنس

التاريخ : ١٤٤٦ / ٧ / ١ هـ ، ٢٠٢٥ / ١ / ١ م

جنري
يحيى غانم

ELISA ASSAY		
TEST	RESULT	N . R .
Calprotectin	18.7 ug/g	Negative < 50.0 ug/g
		Positive > 50.0 ug/g

Signature :